



The Journal of

Clinical *and* Aesthetic Dermatology

A PEER-REVIEWED JOURNAL PROVIDING EVIDENCE-BASED INFORMATION TO PRACTICING CLINICIANS

www.jcadonline.com

VOL. 8, NO. 1 • JANUARY 2015

Special Issue: Common Facial Dermatoses

Atrophic Acne Scarring: A Review of Treatment Options



Efficacy, Safety, and Subject Satisfaction of a Specified Skin Care Regimen to Cleanse, Medicate, Moisturize, and Protect the Skin of Patients Under Treatment for Acne Vulgaris



Comparative Efficacy and Tolerability of Dapsone 5% in Adult Versus Adolescent Females with Acne Vulgaris



Calcium Hydroxylapatite: Over a Decade of Clinical Experience



**Papular Scars:
An Addition to the Acne Scar Classification Scheme**



PLUS: Special American Acne and Rosacea Society Update



Scan this QR code with your QR reader for the digital edition of JCAD.

Presorted Standard
U.S. Postage
PAID
Lebanon Junction, KY
Permit #344

The official journal of



Papular Scars: An Addition to the Acne Scar Classification Scheme

Stephanie D. Gan, MD; Emmy M. Graber, MD, MBA

(*J Clin Aesthet Dermatol.* 2015;8(1):19–20.)

To the editor:

Acne is one of the most common skin diseases, affecting more than 90 percent of adolescents.¹ The severity of acne in adolescents increases with advancing maturity through the teenage years.² Although the prevalence and severity of acne scarring in the population is not

well-documented, the available literature is usually correlated to the severity of acne.³

Acne scars can present with varying morphologies. One morphologic acne scar classification system includes three main types of scars: ice pick, rolling, and boxcar.⁴ Some have also used the term

atrophic scars as a distinct entity or as an all-encompassing term to refer to these types of scars.⁵ Other less common scars include sinus tracts, hypertrophic scars, and keloidal scars. Precise identification of the scar subtype is important in guiding therapeutic management.

Herein, the authors would like to expand the acne scar classification system by adding papular scars to the existing dermatologic lexicon of ice pick, rolling, and boxcar scars (Figure 1). Papular scars are 3 to 4mm skin-colored cobblestone-like papules distributed anywhere on the body but, in our clinical experience, most commonly on the chin (Figure 2a), nose, and back. Also known as white papular acne scars, these flesh-colored papules are often incorrectly diagnosed as acne and do not respond to traditional acne treatments. Histologically, dermal fibrosis consistent with scar is present (Figure 4).

Papular scars can clinically mimic closed comedones, acne, and granulomas, leading to an unnecessary delay in appropriate treatment. Active acneiform lesions causing any type of scars should be treated aggressively with systemic therapy to prevent further progression of scarring.

A more specific and broader classification system is important not only for obtaining an accurate clinical examination, but also for designing targeted studies and treatment protocols for papular scars. Knowledge of this newly described type of acne scar aids in preventing a misdiagnosis of acne and guides appropriate scar-directed management. Future research should be directed toward comparative studies of scar treatments, such as subcision, punch excision, punch elevation, chemical

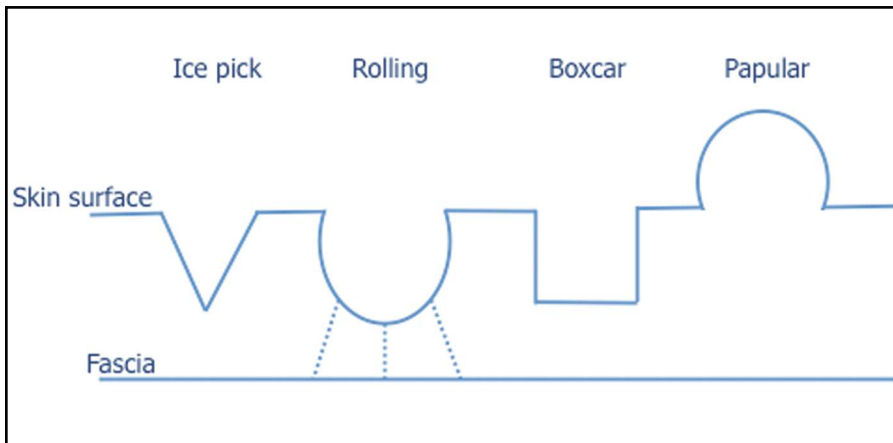


Figure 1. Schematic of acne scar classification system. Ice pick scars are narrow, deep, and extend vertically to the deep dermis or subcutaneous tissue. Rolling scars occur from fibrous anchoring of the dermis to the subcutis, leading to superficial shadowing and an undulating appearance to the overlying skin. Boxcar scars are round-to-oval depressions with sharply demarcated vertical edges. Papular scars, unlike the depressed morphology of ice pick, rolling, and boxcar scars, are exophytic in nature and produce a cobblestone-like appearance.